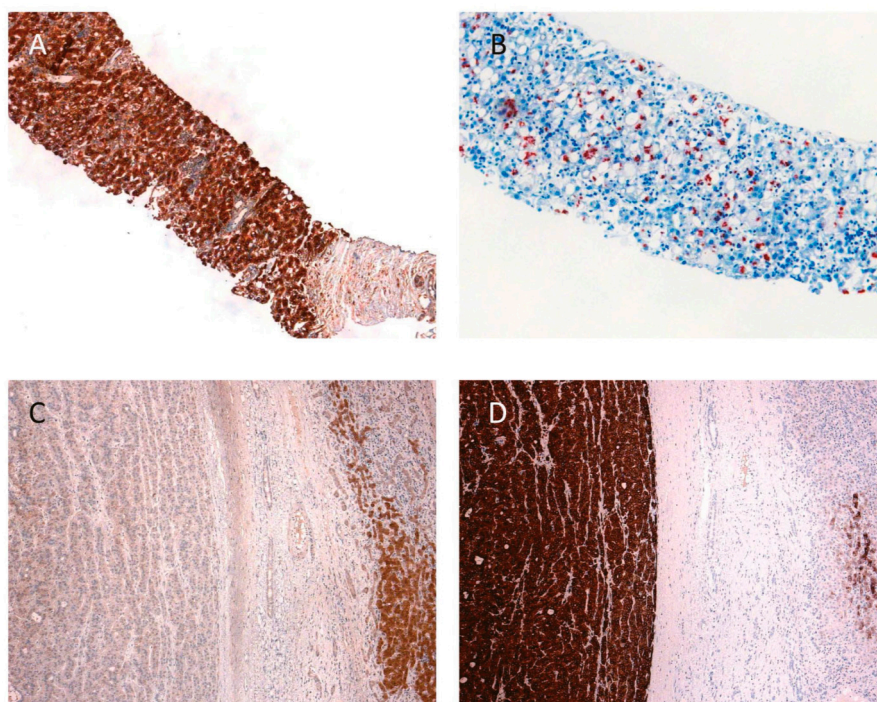


## Supplementary Information



**Figure S1.** Immunohistochemical staining in hepatocellular carcinoma (HCC). (A) Steatohepatic features in HCC are frequently associated with diffuse and intense CRP expression; (B) Ubiquitin staining highlights Mallory Denk bodies underscoring the steatohepatic nature within the same tumor; (C) This HCC displays a loss of FABP (left half) compared to the surrounding liver tissue; and (D) the same tumor shows strong GS staining. CRP: C-reactive protein; FABP: fatty acid binding protein; GS: glutamine synthetase.