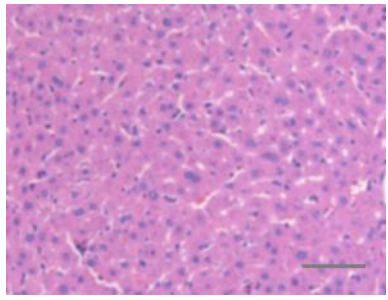
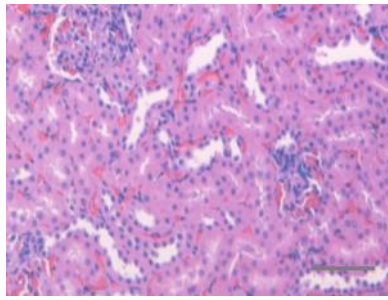
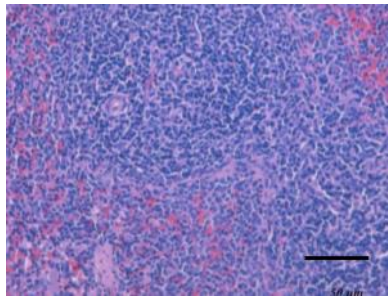
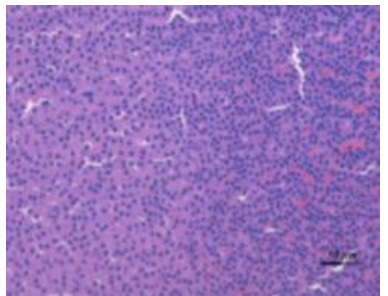


Supplementary Materials: Aerosol Delivery of Surfactant Liposomes for Management of Pulmonary Fibrosis: An Approach Supporting Pulmonary Mechanics

Sabna Kotta, Hibah Mubarak Aldawsari, Shaimaa M. Badr-Eldin, Lenah S Binmahfouz, Rana Bakur Bakhaidar, Nagaraja Sreeharsha, Anroop B. Nair and Chandramouli Ramnarayanan

Organ	Representative Histopathology Image H and E Stained
Liver	
Kidney	
Spleen	
Adrenal gland	

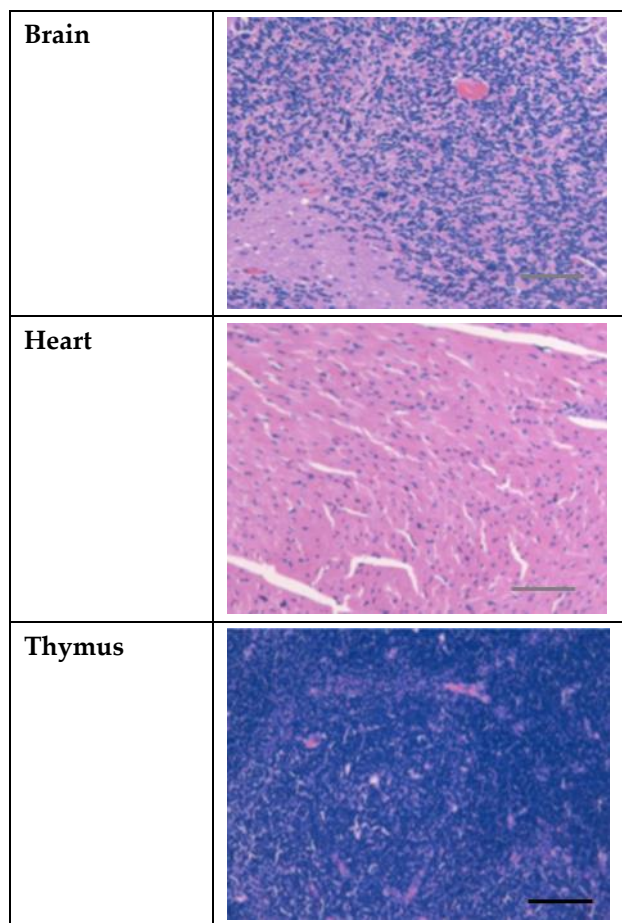


Figure S1. Representative histopathology images of vital organs of the treated group number IV. (Scale bar 0.5 mm = 50 μ m)